



Contents lists available at ScienceDirect

JPRAS Open

journal homepage: [www.elsevier.com/locate/jpra](http://www.elsevier.com/locate/jpra)

## Case Report

## Fibroma of the tendon sheath in the dorsum of the foot: A case report

Risa Nakazawa, Teruyuki Dohi\*, Yuichi Hatsuoka, Ryuta Kigure, Rei Ogawa

*Department of Plastic, Reconstructive and Aesthetic Surgery, Nippon Medical School, Tokyo, Japan*

## ARTICLE INFO

*Article history:*

Received 13 October 2022

Accepted 26 November 2022

Available online 1 December 2022

*Key word:*

Fibroma

Tendon sheath

The dorsum of the foot

Soft tissue tumor

## ABSTRACT

Fibroma of tendon sheath (FTS) is a rare soft tissue tumor that usually occurs in the upper extremity. Moreover, of the few cases reported in the feet, nearly all occur in the plantar region. We report the case of a large FTS in the dorsum of the left foot that grew quickly into a 4 cm-diameter lesion. The 44-year-old Japanese man noticed the tumor incidentally one year before presentation and could not recall any possible cause. Physical examination showed an elastic hard mass that spread over the third to fifth metatarsal bones. MRI showed iso-intense signals with central hypo-intensity on T1-weighted images and hypo-intense signals on T2-weighted images. Since a biopsy did not reveal any malignant findings, the lesion was excised surgically. The tumor was found to be multilocular, encapsulated, and to arise from the extensor digitorum brevis tendon. Histopathology showed scattered spindle fibroblasts and slit-like vascular structures within the dense collagenous matrix. The tumor was diagnosed on the basis of the clinical, demographic, surgical, and histopathological findings as an FTS arising from the extensor digitorum brevis tendon. A review of the literature revealed seven cases of FTS of the dorsum of the foot, which indicates its rarity. More than one-half of these cases were from Japan. While the cause of FTS remains unclear, trauma has been implicated. We suggest that the cultural background of the pa-

\* Corresponding author at: Department of Plastic, Reconstructive and Aesthetic Surgery, Nippon Medical School, 1-1-5 Sendagi Bunkyo-ku, Tokyo 113-8603, Japan.

E-mail address: [dohiprs@gmail.com](mailto:dohiprs@gmail.com) (T. Dohi).

tient, which could promote kneeling-induced dorsal foot trauma, may have contributed to the onset/progression of our case.

Level of Clinical Evidence: 4.

© 2022 The Author(s). Published by Elsevier Ltd on behalf of British Association of Plastic, Reconstructive and Aesthetic Surgeons.

This is an open access article under the CC BY-NC-ND license (<http://creativecommons.org/licenses/by-nc-nd/4.0/>)

## Introduction

Soft tissue tumors of the foot and ankle account for about 4–5% of all musculoskeletal tumors.<sup>1</sup> They range from being exceedingly indolent tumors with no invasive or metastatic potential to highly aggressive malignancies that spread quickly. Since benign and malignant foot/ankle tumors often resemble each other closely clinically, early imaging studies and biopsies are advised.<sup>1</sup>

Fibroma of the tendon sheath (FTS) is a rare benign soft tissue tumor that generally arises from a synovial sheath and grows slowly. It predominantly occurs in the upper extremity, especially the fingers, hands and wrists.<sup>2</sup> FTS of the dorsum of the foot is particularly rare: to our knowledge, only seven cases have been reported to date.<sup>3–9</sup> We report here a case of huge FTS that arose from the extensor digitorum brevis tendon in the dorsum of the foot and grew relatively rapidly.

## Case report

A 44-year-old male incidentally noticed a tumor in the left dorsum of his foot one year ago. In the year after detection, the tumor grew bigger. The patient could not recall a possible lesion onset cause such as trauma. A physical examination showed an elastic, hard, poorly mobile mass that was approximately 4 cm in diameter and spread over the third to fifth metatarsal bones. Compressing the tumor was slightly painful. The left toes did not display any movement or sensory disorders. All laboratory data were normal. Plain X-rays of the left foot were normal. Magnetic resonance imaging (MRI) analysis showed that the tumor was  $3.6 \times 4.6 \times 1.8$  cm in size. It also exhibited an iso-intense signal with central hypo-intensity on T1-weighted images and a hypo-intense signal on T2-weighted images. Contrast-enhanced MRI showed no obvious contrast effect (Figure 1).

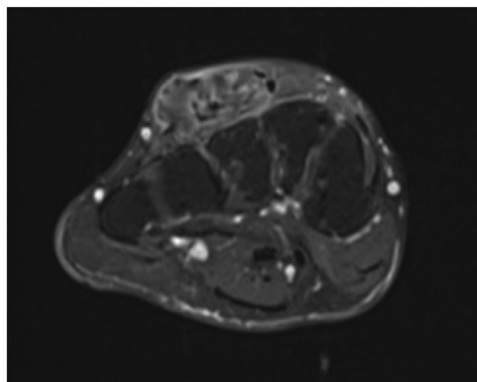
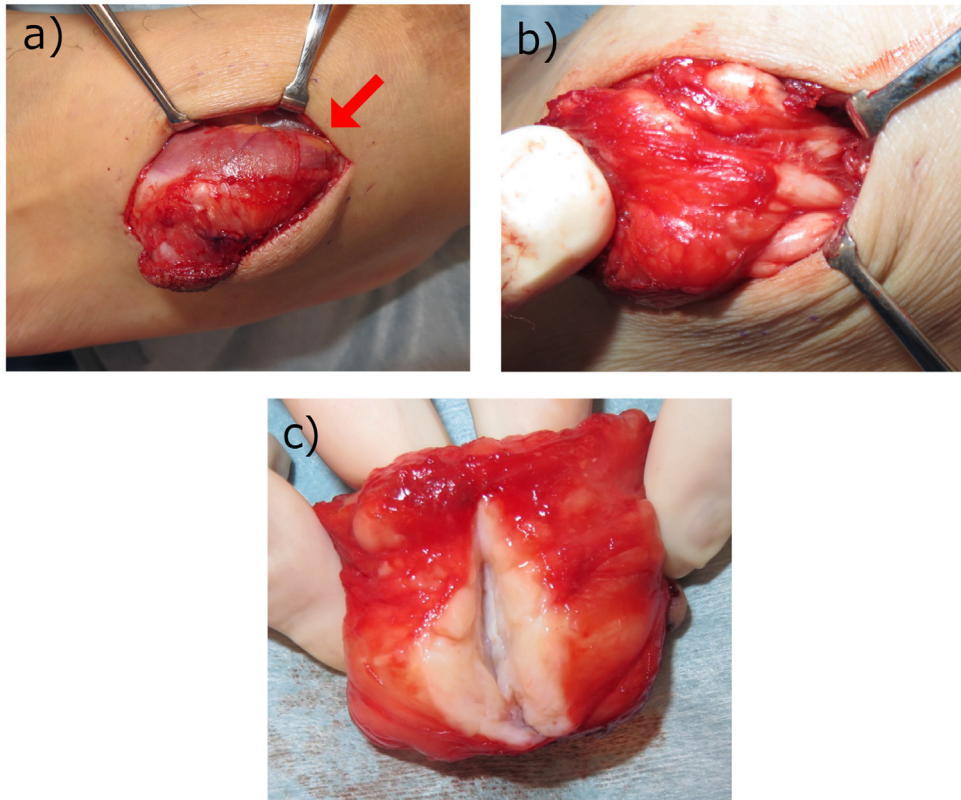


Figure 1. Contrast-enhanced MRI.



**Figure 2.** Surgical findings. (a) Intraoperative findings. The tumor had compressed the neighbor extensor digitorum brevis muscle to the skin side (arrow).(b) The tumor was encapsulated and arose from the extensor digitorum brevis tendon . (c) Macroscopic view of the resected tumor.

Due to the clinical features of the lesion, a partial biopsy was performed under local anesthesia to rule out malignancy. The biopsied material was 1 cm<sup>3</sup> in size and white, hard, and solid. However, malignant findings were not found on histology. Therefore, the entire lesion was excised surgically. The surgery showed that the tumor was multilocular, encapsulated, and arose from the extensor digitorum brevis tendon. The tumor had also compressed the neighboring extensor digitorum brevis muscle and extensor digitorum longus tendon to the skin side. The tumor was white, smooth, solid, and multilocular (Figure 2). Histopathological analysis showed scattered spindle fibroblasts and slit-like vascular structures within the dense collagenous matrix. No multinucleated giant cells or atypical cells were observed.

These findings and the clinical features led to a diagnosis of FTS arising from the extensor digitorum brevis tendon. The postoperative period was uncomplicated and movement or sensory disorders or recurrence were not observed one year after surgery.

## Discussion

In 1936, Geshickter and Copeland described the first case of FTS and 43 years later, Chung and Enzinger reported the characteristics of 138 cases of FTS. The latter report remains the largest series on FTS. In particular, they noted that 98% of the FTS occurred in the extremities, particularly the flexor surfaces. Moreover, of the 136 extremity FTS, only 13% ( $n = 17$ ) occurred in the lower extremity. Foot FTS accounted for 30% of the lower extremity FTS ( $n = 5$ ).<sup>2</sup>

FTS incidence is highest in the third to fifth decade of life and the male to female ratio is 1.5–3 to 1. FTS is generally painless but tenderness/discomfort or radiating pain due to the tumor compressing the surrounding tissues is sometimes reported.<sup>3,4</sup> MRI imaging usually shows low to iso-intensity on T1-weighted images and low to slight high-intensity signals on T2-weighted images.<sup>5</sup>

FTS appears as a fibrous nodule that is attached to a tendon or tendon sheath. It is benign and slow-growing. The macroscopic view after surgery is a white, smooth, dense, and multilocular tumor that ranges from 0.5 to 7 cm in diameter. Our case was  $3.6 \times 4.6 \times 1.8$  cm, which indicates it was relatively big. Pathology reveals scattered spindle- or star-shaped fibroblasts cell in a dense collagenous matrix along with slit-like vascular structures. Atypical or inflammatory cells are usually absent.<sup>2</sup>

The differential diagnoses for malignant soft tissue tumors include malignant fibrous histiocytoma, synovial sarcoma, leiomyosarcoma, and malignant peripheral nerve sheath tumor, while the differential diagnoses for benign soft tissue tumors are giant cell tumor of the tendon sheath (GCTS), nodular fasciitis, extra-abdominal desmoid tumor, ganglion, neurofibromatosis, leiomyoma, pigmented villonodular synovitis (PVNS), scar, and others. In clinical practice, the most important differential diagnosis for FTS is GCTS. It is difficult to discriminate between the two on the basis of clinical findings: although FTS tends to occur at a younger age and more frequently in males, both FTS and GCTS have the same predilection for tendon sheaths, multinodular phenotype, and high recurrence rates. Histopathology drives the differential diagnosis: FTS associates with more severe fibrosis in the matrix, more abundant spindle-shaped cells, few giant cells, and no foam cells or siderophages.<sup>2</sup>

The standard treatment of FTS is surgical excision. However, since FTS tends to adhere strongly to the surrounding tissue, it can be difficult to determine how much tissue to resect, especially because the recurrence rate after surgical treatment is high (20–24%). In terms of follow-up, Lüdke et al. suggested that follow-up should last for at least three years.<sup>10</sup>

FTS of the dorsum of the foot is very rare. When we searched PubMed, Scopus, and Ichushi web (a database of Japanese medical literature) with the search terms "fibroma of tendon sheath" AND "foot" OR "back/dorsum of the foot" OR "extensor digitorum brevis muscle", we only found seven cases.<sup>3-9</sup> Notably, four of the cases were in Japan, one in the United States, one in the United Kingdom, and one in India. We speculate that the more frequent reportage in Japan may reflect greater rates of trauma to the dorsum of the foot. Specifically, approximately 10% of FTS cases are reported to be caused by an obvious history of trauma, and friction has been suggested to initiate and/or promote soft tissue sclerosis.<sup>2</sup> This may explain, at least in part, why FTS predominantly occurs in the upper extremity: the hands and fingers contain many small joints that are frequently exposed to mechanical forces. This may also explain why FTS on the foot is rare and is almost always in the plantar region: the dorsum of the foot is usually at less risk of trauma. However, in Japan and unlike in Europe and the United States, people often sit in the "seiza" posture, namely, kneeling with the dorsa of the feet flat on the floor. This may increase the risk of trauma to the foot dorsum. In our case, there was no trauma history and thus the cause of his FTS was unclear. Nonetheless, it seems possible that his cultural background/lifestyle could have contributed to the onset and/or progression of his FTS.

## Conclusion

We report a rare case of FTS at the dorsum of the foot. The diagnosis was made on the basis of clinical, demographic, surgical, and histopathological characteristics. While the cause of FTS was unclear, we suggest that the patient's cultural background/lifestyle may have initiated and/or promoted the growth of the lesion.

## Informed consent

Informed consent to include case details and images in our publication was obtained from the patient.

## Ethical statement

Not applicable.

## Conflict of Interest

None.

## Funding

None.

## References

1. Rammelt S, Fritzsche H, Hofbauer C, Schaser K. Malignant tumours of the foot and ankle. *Foot Ankle Surg.* 2020;26:363–370. doi:10.1016/j.fas.2019.05.005.
2. Chung EB, Enzinger FM. Fibroma of tendon sheath. *Cancer.* 1979;44:1945–1954.
3. Kinoshita G, Iwata Y, Yamada H, et al. A case of fibroma of tendon sheath of the dorsal foot. *Clinic Orthop Surg.* 1991;26(12):1419–1422.
4. Kumar A, Patel J, Bansal A, Rawat S, Sethi K. Tendon sheath fibroma of fore foot a rare case report. *Int J Adv Res.* 2017;5(2):680–684. doi:10.21474/IJAR01/3201.
5. Nomura T, Nagai M, Matsuda S, et al. Fibroma of tendon sheath on the dorsum of the foot: a case report. *J Jpn PRS.* 2019;39(7):328–332.
6. Sarma DP, Townsend GH, Rodriguez Jr FH. Fibroma of tendon sheath. *J Foot Surg.* 1987;26:422–424.
7. Lourie JA, Lwin KY, Woods CG. Case report 734. *Skeletal Radiol.* 1992;21:273–275.
8. Shimizu H, Maekawa J, Hosono M, et al. A case of fibroma of tendon sheath on the dorsum of the foot. *Jpn J Plast Surg.* 2010;53(8):909–913.
9. Takami Y, Makuuchi H. A case of fibroma of tendon sheath in the toes. *Skin Surg.* 2018;27:100–102.
10. Lüdke E, Kohut G, Bäcker HC, Maniglio M. Is the recurrence of fibroma of tendon sheath underestimated? An instructive case report and a review of the literature. *Case Rep Orthop.* 2020;5357329. doi:10.1155/2020/5357329.