



ELSEVIER

Contents lists available at ScienceDirect

JPRAS Open

journal homepage: www.elsevier.com/locate/jpra



Original Article

Epicanthus correction with a modified asymmetric Z-plasty

Gaofeng Li*, Anqi Fu, Bo Zhang, Wei Ding, Huawei Ouyang, Suqi Xu, Xiren Long, Xiaojia Liu

Department of Plastic and Cosmetic Surgery, Hunan Provincial People's Hospital, The First Affiliated Hospital of Hunan Normal University, Changsha, Hunan Province P.R. China

ARTICLE INFO

Article history:

Received 31 January 2022

Accepted 27 February 2022

Available online 17 March 2022

Keywords:

Epicanthus correction

Asymmetric Z-plasty

Modified

Medial Canthus

ABSTRACT

The study aimed to explore the clinical efficacy of the modified asymmetric Z-plasty with a central axis from the point near the edge of the skin fold of the medial canthus to the point of the innermost palpebral edge of medial canthus for epicanthus correction. A total of 130 followed-up patients who received modified asymmetric Z-plasty for epicanthus correction in Hunan Provincial People's Hospital from January 2019 to December 2019 were included. All patients were followed up with at 1, 3, and 6 months after surgery, and the scarring and surgical outcomes were assessed. The results showed the surgical wounds were healing well, and the sutures were removed at 7 days postoperatively in all patients. At 6 months postoperatively, epicanthus correction was successful in all patients, the lacrimal caruncle was moderately exposed, the incision was not red, and there were no obvious prominent scars. Slightly prominent and uneven scars below the edge of the lower eyelid were observed in 3 patients. Among these 3 patients, 1 patient received no further treatment, and the outcomes were considered acceptable; the outcomes were improved in the remaining 2 patients after a single session of fractional laser treatment, and none of these patients received further surgery. In conclusion, the

* Corresponding author: Gaofeng Li, 61 Jiefangxi road, Changsha 410005, Hunan Province P.R.China, Tell: +86-0731-84422357, Fax: +86-0731-82278011

E-mail address: ligf01@126.com (G. Li).

modified asymmetric Z-plasty with a central axis from the point near the edge of the skin fold of the medial canthus to the point of the innermost palpebral edge of medial canthus is relatively simple and provides good surgical results for epicanthus correction.

© 2022 The Author(s). Published by Elsevier Ltd on behalf of British Association of Plastic, Reconstructive and Aesthetic Surgeons.

This is an open access article under the CC BY-NC-ND license (<http://creativecommons.org/licenses/by-nc-nd/4.0/>)

Since 2009, we have used asymmetric Z-plasty with a two-curve design to correct epicanthus and achieved good clinical outcomes.¹ However, in some cases, more tissue needs to be trimmed after Z-flap rotation, which increases the uncertainty of the surgical outcomes. To simplify the surgical procedures and obtain reliable results, we modified this Z-plasty technique in 2017. Herein, we present our new modified asymmetric Z-plasty with a central axis from the point near the edge of the skin fold of the medial canthus to the point of the innermost palpebral edge of medial canthus.

Patients and methods

Patients

The study cohort comprised 130 followed-up patients with epicanthus who received the new modified asymmetric Z-plasty in Hunan Provincial People's Hospital from January 2019 to December 2019. There were 122 females and 8 males, and the age range was 17 to 43 years. All patients had bilateral epicanthi, including 20 patients with mild epicanthi, and 110 patients with moderate to severe epicanthi.

Methods

Preoperative design

Points A, B, C, and D were positioned as described below. Point B was at the original medial canthus point position which was the point of the innermost palpebral edge of medial canthus. The projected position of the original medial canthus point position (point B on the skin surface of the epicanthal fold) was considered the new medial canthus point position and was described as point A. Point C was located near the edge of the skin fold of the medial canthus. The lengths AC, BC, and AB were equal (i.e., $AC = BC = AB$). Point D was placed at the palpebral edge of the lower eyelid, so that the distance between points B and D was the same as that between points A and B (i.e., $BD = AB$). The three lines from points A to C, B to C, and B to D were connected. These lines formed the asymmetric Z-plasty incision, with line BC as the central axis, and lines AC and BD as the two arms of the asymmetric Z. The design of the asymmetric Z-plasty is shown in [Figures 1 and 2](#).

Surgical procedure and follow-up

After the incision lines were drawn, the surgical field was disinfected and covered with a sterile surgical drape. After the administration of local anesthesia with 2% lidocaine and 1:100,000 epinephrine solution, a no. 11 scalpel blade was used to incise the skin down to the subcutaneous tissue along lines BD, BC, and AC. The subcutaneous tissue was separated and released using scissors, and part of the subcutaneous white fibrous tissue was removed. After being released, the triangular flap ACB was transposed to fill the opening of the incision BD. A small amount of “dog ear” usually formed at the junction of BC and BD; this was carefully removed to ensure that BC and BD were flat and fit perfectly. Each incision was sutured in an intermittent pattern with 7-0 nylon sutures under completely tension-free conditions. If double-eyelid blepharoplasty was performed simultaneously, the

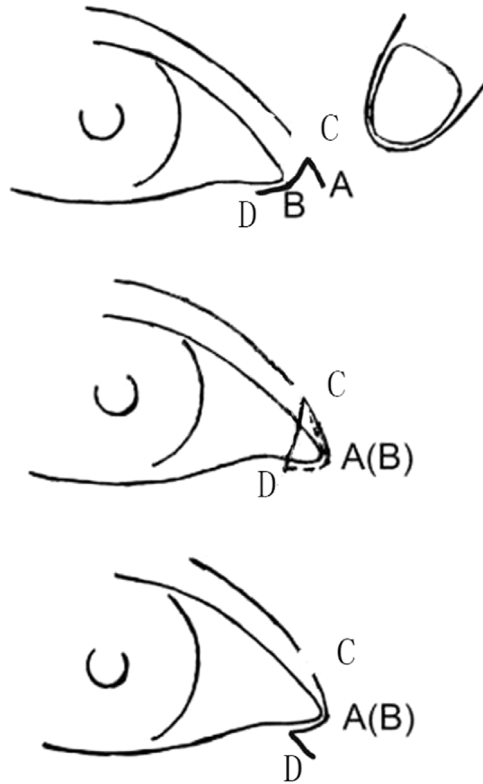


Figure 1. Schematic diagram of the modified asymmetric Z-plasty used from 2017 onwards.

procedure was performed after epicanthus correction. At 7 days postoperatively, the sutures were removed, and the patients were then photographed. All patients were followed up through follow-up visits or WeChat at 1, 3, and 6 months after surgery, and the scarring and surgical outcomes were assessed.

Results

In all patients, the surgical wounds were healing well, and the sutures were removed at 7 days postoperatively. At 1 month postoperatively, 83 patients reported scarring of the medial canthi; most scars were slightly red and relatively flat, while 9 patients had scars that appeared more red, prominent, and hard. At 3 months postoperatively, the scar redness had subsided in most patients; however, 5 patients still had slightly prominent scars. At 6 months postoperatively, epicanthus correction was judged to be successful in all patients; the lacrimal caruncle was moderately exposed, the incision was not red, and there were no obvious prominent scars. Three patients had slightly prominent and uneven scars below the margin of the lower eyelid. One of these three patients received no further treatment, and the outcomes were considered acceptable; the outcomes were improved in the remaining two patients after a single session of fractional laser treatment, and none of these patients received further surgery. Typical case results are shown in [Figure 3](#).

Discussion

There is a high prevalence of epicanthus in the oriental races.² In accordance with the degree to which the epicanthus covers the lacrimal caruncle, the severity of epicanthus is classified as mild,

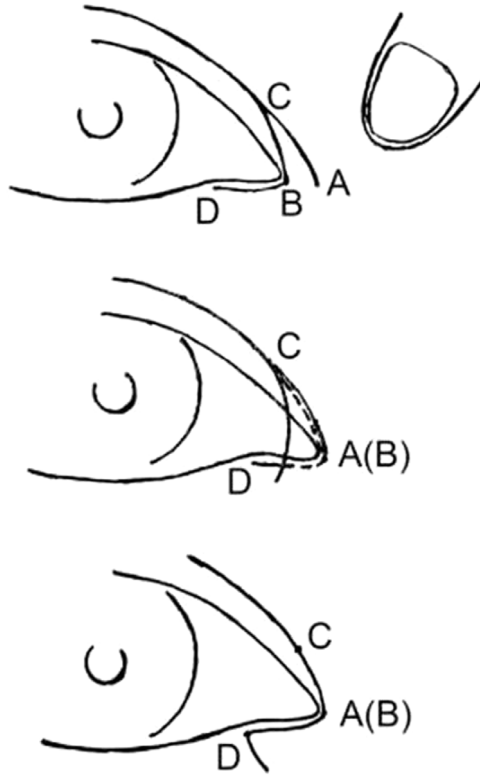


Figure 2. Schematic diagram of the original asymmetric Z-plasty used before 2017.

moderate, and severe. The decision to correct mild epicanthus is primarily dependent on the patient's wishes. Moderate to severe epicanthus has a greater impact on the shape of the double eyelids, and we generally advocate correction along with double-eyelid blepharoplasty.

There are two main reasons for epicanthus formation: (1) abnormal subcutaneous adhesions in the skin of the medial canthal region form abnormal skin tension and result in the displacement of medial canthal skin; (2) the prolonged effect of abnormal skin tension leads to excess horizontal skin and insufficient vertical skin in the medial canthal region.¹ Therefore, the key to correct epicanthus is to release the abnormal subcutaneous adhesions in the medial canthal skin, relieve the abnormal skin tension, increase the amount of vertical medial canthal skin, and reduce the vertical tension.^{3,4}

There are many methods for correcting epicanthus, including the transverse incision method, Y-V-plasty, transverse incision with vertical closure, and Z-plasty.^{2,5} Z-plasty not only corrects the excess horizontal medial canthal skin but also corrects the vertical skin deficiency through the transposition of the triangular flap.⁶ Z-plasty is a classic method for the correction of epicanthus. In the classic Z-plasty, the central axis is located at the edge of the skin fold of the medial canthus; after the two triangular tissue flaps are transposed, the incision is over the edge of the medial canthus and located on the skin surface at the side of nose, causing a visible scar. To avoid this shortcoming, we modified the Z-plasty design in 2009. In our original modified Z-plasty, the central axis of the "Z" is moved inward, with the intersection between the superior edge of the skin fold of the medial canthus and the double-eyelid line as the starting point, and the point of the innermost palpebral edge of medial canthus as the end point. The advantage of this original modified Z-plasty design is that after transposition of the triangular flap, the incision is not over the medial canthus, and there is no incision located on the skin surface of the nasal side, thus avoiding the disadvantages of the classic Z-plasty.¹ However, during the clinical application, we found that the starting point of the central axis varied

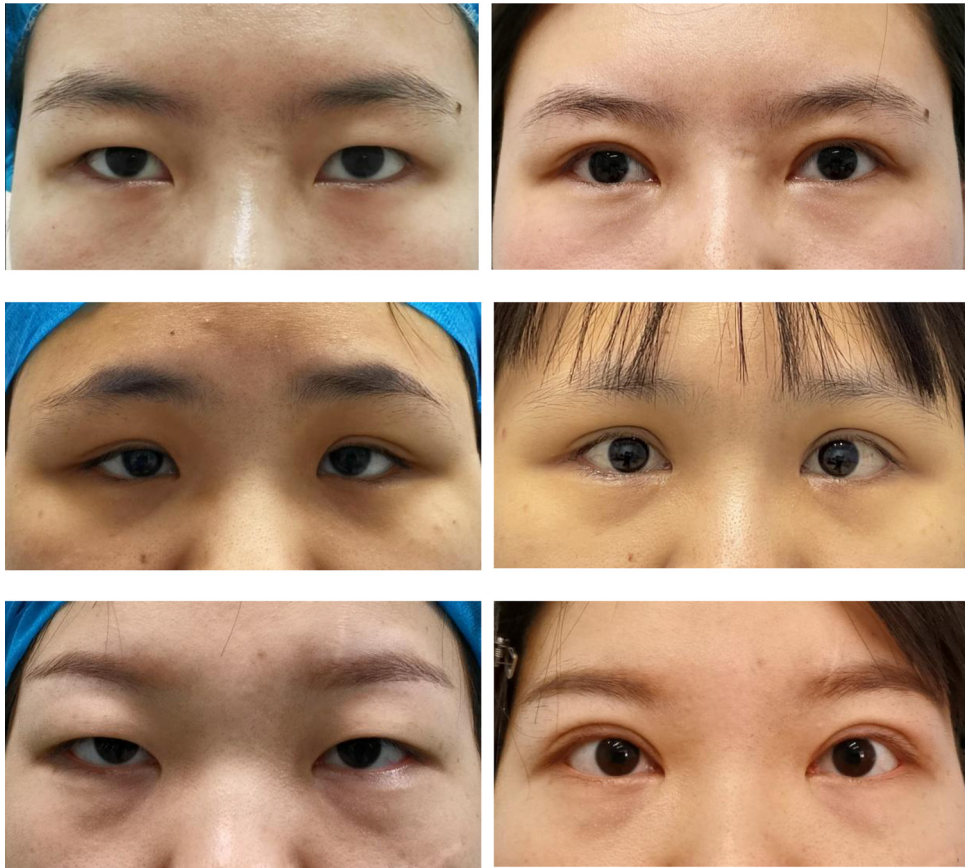


Figure 3. Typical cases. Above (left), Preoperative image of case 1 of mild epicanthus. Above (right), Six-month postoperative image of case 1. Middle (left), Preoperative image of case 2 of moderate epicanthus. Middle (right), Six-month postoperative image of case 2. Below (left), Preoperative image of case 3 of severe epicanthus. Below (right), Six-month postoperative image of case 3.

greatly between individuals. After the created triangular flaps were transposed and located below the medial canthus, the flaps often did not fit perfectly into the incision, and more tissue needed to be trimmed to achieve a flat fit. However, even after the tissue was trimmed, some patients still had uneven topography below the medial canthus.

To overcome this shortcoming, we modified the original design of the asymmetric Z-plasty with a two-curve design; no change was made to the design of the original medial canthus point position (point B) and the new medial canthus point position (point A), but the positions of points C and D were modified. In the original asymmetric Z-plasty design, point C is located at the intersection between the skin fold of the medial canthus and the double-eyelid line, and point D is located at the palpebral edge of the lower eyelid, below the lacrimal punctum. Using this original asymmetric Z-plasty design, the length of AC is often not equal to that of BC, and the length of BC is not equal to that of BD. Therefore, after the triangular flap is transposed, more tissue needs to be trimmed, which increases the number of steps in the surgical procedure and decreases the reliability of the surgical results. To simplify the surgical procedure and improve the reliability of the surgical outcomes, the position of point C was adjusted to ensure that AC, BC, and AB were the same (i.e., $AC = BC = AB$), so that the three points A, B, and C formed an equilateral triangle. Furthermore, point D was located at the palpebral edge of the lower eyelid, and the length of BD was equal to that of AB (i.e., $BD = AB$).

In the modified design, the transposed triangular flap ACB filled the opening of the incision BD and fit perfectly into the incision. The flap ACB did not require trimming, and only minimal trimming of the dog ear formed at the junction of BC and BD was required. This new modified design not only simplified the surgical procedure but also reduced the incidence of uneven topography below the medial canthus after surgery.

In summary, for the correction of epicanthus, the new modified asymmetric Z-plasty with a central axis from the point near the edge of the skin fold of the medial canthus to the point of the innermost palpebral edge of medial canthus is relatively simple and provides good surgical results.

Funding

None

Ethical approval

Not required

Patient consent for photo publication

Written consent has been obtained

Declaration of Competing Interest

None declared

References

1. Li G, Wu Z, Tan J, Ding W, Luo M. Correcting epicanthal folds by using asymmetric Z-plasty with a two curve design. *J Plast Reconstr Aesthet Surg.* 2016;69(3):438–440 Mar.
2. Wang S, Shi F, Luo X, Liu F, Zhou X, Yang J, Yang Q, Wang X. Epicanthal fold correction: our experience and comparison among three kinds of epicanthoplasties. *J Plast Reconstr Aesthet Surg.* 2013;66(5) May682–7.
3. Park JW, Hwang K. Anatomy and Histology of an Epicanthal Fold. *J Craniofac Surg.* 2016;27(4):1101–1103 Jun.
4. Sung Y, Lew H. Epiblepharon correction in Korean children based on the epicanthal pathology. *Graefes Arch Clin Exp Ophthalmol.* 2019;257(4):821–826 Apr.
5. Lee TY, Shin YH, Choi DI. Reconstruction of medial epicanthal fold using v-y advancement and turnover flap. *J Plast Reconstr Aesthet Surg.* 2020;73(2):363–368 Feb.
6. Park JI. Z-epicanthoplasty in Asian eyelids. *Plast Reconstr Surg.* 1996;98:602.